

Clinical Guidelines and Prosthodontic Considerations for Establishing Occlusion in Class II Jaw Relations: A Narrative Review

Kalamalla A SaranBabu*, Poojitha Y, Sunke Anuradha, Devarapalli Sai Tejaswi, Mano Kumar Paturu, CH.Deepika

Department of Prosthodontics, Narayana Dental College & Hospital, Nellore, Andhra Pradesh, India

ABSTRACT

Background: Successful prosthodontic rehabilitation depends on the establishment of stable and functional occlusion. Most traditional occlusal concepts in restorative dentistry are based on Class I skeletal relationships. However, a considerable proportion of patients present with Class II jaw relations characterized by mandibular retrusion relative to the maxilla. These anatomical variations may alter occlusal contacts, mandibular movement patterns, and force distribution during mastication, thereby creating unique biomechanical challenges in prosthodontic treatment. **Objective:** The purpose of this review is to analyze the anatomical and functional characteristics of Class II jaw relations and to discuss occlusal considerations that should be incorporated into prosthodontic rehabilitation for such patients. **Methods:** Relevant literature related to occlusion, mandibular movement, and prosthodontic rehabilitation in Class II jaw relations was reviewed. Foundational works on occlusion, mandibular biomechanics, and prosthodontic treatment principles were examined to identify clinically applicable guidelines for occlusal design. **Results:** Class II jaw relations are commonly associated with mandibular retrognathia, increased overjet, deep overbite, altered condylar positioning, and reduced posterior facial height. These morphological variations influence anterior guidance, posterior occlusal contacts, and the envelope of mandibular motion. Prosthodontic treatment in such patients often requires modifications in occlusal morphology, including reduced cusp height, shallow fossae, and controlled anterior guidance. Careful management of centric relation and centric occlusion discrepancies is also essential to prevent occlusal interferences and abnormal loading of restorations. **Conclusion:** Prosthodontic rehabilitation in patients with Class II jaw relations requires individualized occlusal planning that accounts for altered mandibular movement patterns and occlusal relationships. Incorporating appropriate occlusal modifications and maintaining functional harmony between anterior and posterior teeth can improve prosthetic stability, minimize occlusal interferences, and enhance long-term clinical outcomes.

Keywords: Class II Jaw Relation, Occlusion, Prosthodontics, Mandibular Retrognathia, Anterior Guidance, Bilateral Balanced Occlusion.

Vol No: 10, Issue: 01

Received Date: March 13, 2026

Published Date: April 17, 2026

*Corresponding Author

Dr. Kalamalla A SaranBabu,

Associate Professor, Department of Prosthodontics, Narayana Dental College and Hospital, Nellore, Andhrapradesh, India, Tel: 8886078222, Email: ayappasaranbabu@gmail.com

Citation: SaranBabu KA, et al. (2026). Clinical Guidelines and Prosthodontic Considerations for Establishing Occlusion in Class II Jaw Relations: A Narrative Review. Mathews J Dentistry. 10(1):65.

Copyright: SaranBabu KA, et al. © (2026). This is an open-access article distributed under the terms of the Creative Commons Attribution License, which permits unrestricted use, distribution, and reproduction in any medium, provided the original author and source are credited.

INTRODUCTION

Occlusion plays a fundamental role in the success of prosthodontic rehabilitation, influencing masticatory efficiency, temporomandibular joint function, and the longevity of restorations. Improper occlusal relationships can lead to occlusal interferences, abnormal muscle activity, and increased biomechanical stress on prostheses, ultimately resulting in restoration failure or patient discomfort [1]. Contemporary prosthodontics increasingly emphasizes functional harmony and individualized occlusal design, particularly with the advent of advanced restorative materials and digital technologies [2].

Most traditional occlusal concepts and treatment philosophies have been developed based on Class I skeletal relationships. However, these concepts may not be directly applicable to patients with skeletal discrepancies such as Class II jaw relations. Class II malocclusion, characterized by a retruded mandible and increased overjet, is one of the most prevalent dentofacial variations and presents unique functional and biomechanical challenges during treatment planning [3]. Recent evidence highlights that managing such cases—especially when combined with conditions like tooth wear—remains complex and often lacks standardized prosthodontic guidelines [4].

Despite extensive literature on occlusion, there is a relative lack of focused synthesis addressing occlusal considerations specifically tailored to Class II jaw relations in prosthodontic rehabilitation. Existing studies often emphasize orthodontic correction or general occlusal theories, with limited translation into clinically applicable prosthodontic protocols.

Therefore, the purpose of this narrative review is to critically

analyze the anatomical and functional characteristics of Class II jaw relations and to synthesize clinically relevant occlusal guidelines for prosthodontic rehabilitation.

The specific objectives are:

1. To evaluate the skeletal and functional features influencing occlusion in Class II patients.
2. To analyze their impact on anterior guidance, posterior occlusion, and mandibular movement patterns.
3. To identify and propose clinically applicable modifications in occlusal design for prosthodontic treatment.

Prevalence and Clinical Significance of Class II Jaw Relations

In dental practice, one of the most common skeletal malocclusions is Class II jaw relation. Epidemiological studies suggest that approximately 15–20% of individuals may exhibit a Class II skeletal relationship to varying degrees [5]. Beyond aesthetic concerns, Class II occlusion has important clinical implications because the altered relationship between the maxilla and mandible influences mastication, speech, and temporomandibular joint mechanics [4,6,7].

Applying conventional Class I occlusal concepts to Class II patients increases the risk of occlusal discrepancies. Restorations fabricated without considering these variations may produce premature contacts and interferences because mandibular movement patterns differ from those seen in Class I relationships [1]. Therefore, understanding the biomechanical implications of Class II jaw relations is essential for achieving predictable outcomes in prosthodontic therapy (Table 1).

Table 1. Key Literature on Occlusal Considerations in Class II Jaw Relations

Author (Year)	Study Type	Main Focus	Key Findings	Clinical Relevance
Jensen WO (1990)	Review	Occlusal considerations in Class II	Highlighted need for modified occlusal schemes	Foundation for prosthodontic occlusal modifications
Posselt U (1957)	Functional analysis	Envelope of mandibular motion	Described mandibular movement envelope	Important for prosthetic design within functional range
Dawson PE (2007)	Clinical text	Functional occlusion	Explained centric relation and occlusal harmony	Essential for prosthodontic rehabilitation
Okeson JP (2019)	Clinical reference	TMJ and occlusion	Discussed mandibular movement mechanics	Helps understand occlusal dynamics
Wiskott & Belser (1995)	Review	Simplified occlusal design	Suggested reduced cusp inclination	Useful for Class II restorative design
Zarb et al. (2012)	Prosthodontic text	Complete denture occlusion	Explained bilateral balanced occlusion	Relevant for edentulous Class II patients

Skeletal and Morphological Characteristics

Class II jaw relationships are commonly associated with distinctive craniofacial characteristics that influence mandibular movement and occlusion. Mandibular retrognathia, where the mandible is positioned posteriorly relative to the maxilla, is one of the most frequently observed features. This retruded mandibular position leads to increased horizontal overlap between anterior teeth, commonly referred to as overjet [5,8,9].

Additional skeletal features may include an increased mandibular plane angle, a shortened mandibular body, and reduced ramus height. These anatomical variations can

alter occlusal plane orientation and influence the vertical dimension of occlusion [8].

Furthermore, the mandibular condyles may occupy a different position within the glenoid fossae compared with Class I individuals. In many Class II cases, the condyles are positioned more superiorly and posteriorly within the fossae. This altered condylar position can influence condylar movement during mandibular excursions [10].

The most common skeletal and morphological characteristics of Class II jaw relations and their prosthodontic implications are summarized in (Table 2).

Table 2. Common Morphological Characteristics of Class II Jaw Relations

Future	Description	Prosthodontic Implication
Mandibular retrognathia	Posterior position of mandible	Alters occlusal contact pattern
Increased overjet	Large horizontal overlap	Alters anterior guidance
Deep overbite	Increased vertical overlap	Steep incisal guidance
Reduced posterior facial height	Short lower face height	May affect vertical dimension
Posterior condylar position	Condyle positioned posteriorly	Alters mandibular movement pathway

Functional Role of Anterior Teeth

Anterior teeth play an important role in guiding mandibular movements and protecting posterior teeth from excessive lateral forces. In Class II patients, the functional role of anterior teeth is often altered due to increased overjet and deep overbite.

In patients with deep overbite, the vertical component of incisal guidance may become steeper. Incisal guidance refers to the influence of anterior tooth contact on mandibular movement [11-13]. Increased overjet may also introduce a larger horizontal component to anterior guidance. These

changes can significantly affect posterior disclusion during eccentric movements.

In some cases, posterior teeth may fail to disclude effectively during lateral or protrusive movements due to altered anterior guidance geometry. This lack of posterior disclusion can result in detrimental occlusal contacts and increased stress on prosthetic restorations [14-16].

The biomechanical differences between Class I and Class II occlusion that influence anterior guidance and mandibular movement are illustrated in Figure 1.

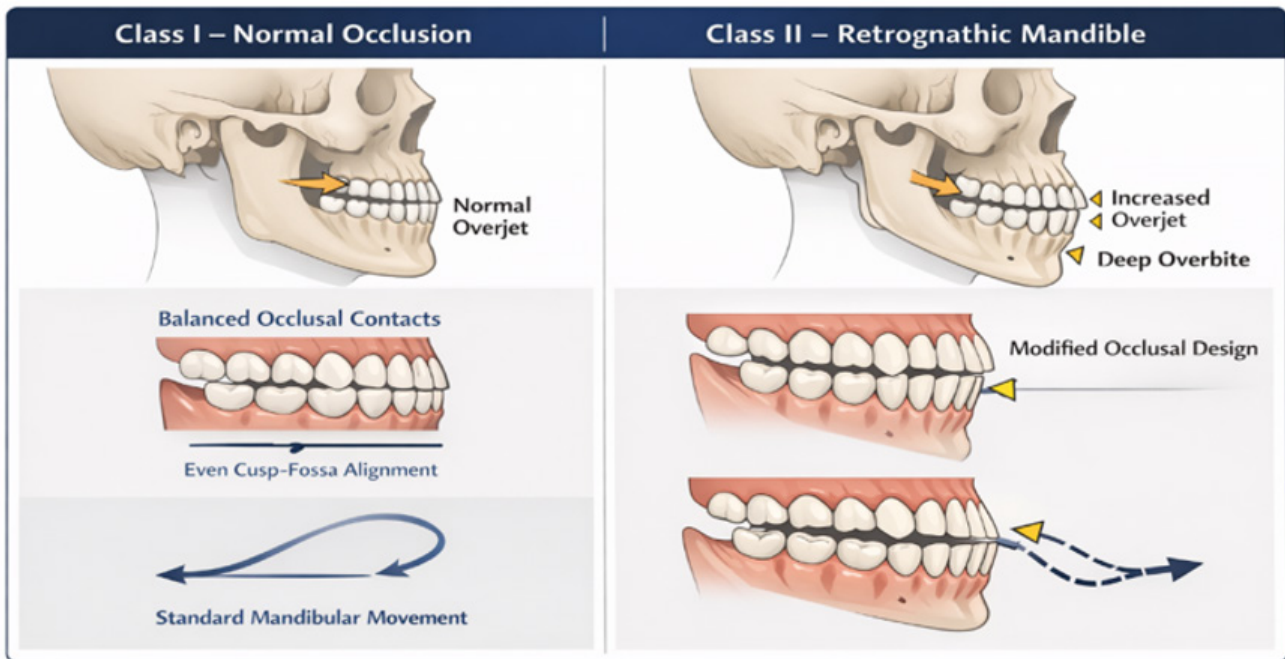


Figure 1. Comparison of Occlusal Relationships in Class I and Class II Skeletal Patterns.

Posterior Occlusion in Class II Patients

Posterior teeth bear the majority of occlusal forces during mastication. In Class II patients, the typical cusp-fossa relationships observed in Class I occlusion may not apply between maxillary and mandibular posterior teeth.

Standard cusp heights and occlusal inclines commonly used in Class I restorations may create premature contacts when applied to Class II patients. This occurs because the pathway of mandibular movement during function differs from the path assumed in traditional occlusal designs [17,18].

To reduce the likelihood of occlusal interference, modifications to posterior occlusal morphology are often recommended. Reduced cusp height, shallow fossae, and wider occlusal tables can accommodate altered mandibular movement patterns and minimize lateral forces [19].

Recommended occlusal design modifications for prosthodontic rehabilitation in Class II patients are summarized in Table 3.

Table 3. Recommended Occlusal Modifications for Class II Prosthodontic Rehabilitation

Occlusal Parameter	Modification	Clinical Purpose
Cusp height	Reduced cusp inclination	Minimize lateral forces
Occlusal fossae	Shallow fossae	Allow freedom of movement
Occlusal table width	Slightly widened	Accommodate altered mandibular path
Anterior guidance	Controlled guidance angle	Maintain posterior disclusion
Occlusal scheme	Canine guidance or proupp function	Distribute occlusal forces

Centric Relation and Centric Occlusion

Centric relation and centric occlusion are fundamental concepts in prosthodontic occlusion. Centric relation describes the physiologic relationship between the condyles and the articular eminences when the mandible is in its most stable and reproducible position [6]. Centric occlusion, or maximum intercuspation, refers to the position where the teeth achieve maximum contact.

In patients with Class II jaw relations, centric relation and centric occlusion may not coincide. The discrepancy between these positions may be greater than that observed in Class I individuals [1].

Accurate recording of jaw relations and articulator programming are essential for simulating mandibular movements during laboratory procedures and preventing occlusal interferences.

Working Side Movements

During lateral mandibular movement, the side toward which the mandible moves is referred to as the working side. The condyle on the working side primarily rotates while the opposite condyle translates along the articular eminence [4].

Canine guidance is often considered the preferred occlusal scheme for working side movements because it promotes posterior disclusion and reduces lateral forces on posterior teeth and restorations [13]. However, when canine guidance cannot be established, group function may serve as an alternative occlusal scheme to distribute occlusal forces across multiple teeth [16].

Balancing Side Contacts

The balancing or non-working side is the side opposite to the direction of mandibular movement during lateral excursions. Contacts on this side are generally considered undesirable in fixed prosthodontics because they may introduce destabilizing forces [1].

In complete denture prosthodontics, however, balancing contacts are necessary to maintain denture stability. Bilateral balanced occlusion allows simultaneous contact of teeth on both sides of the arch during functional movements, preventing denture tipping [3].

Protrusive Movements

Protrusive movement occurs when the mandible moves anteriorly from its intercuspal position. During this movement, both condyles translate downward and forward along the slopes of the articular eminences [4].

In Class II patients, increased overjet and deep overbite can influence protrusive movement patterns and alter anterior guidance pathways. Ideally, posterior teeth should separate immediately during protrusion so that anterior teeth guide mandibular movement and prevent occlusal interference [13,17,18].

Envelope of Mandibular Motion

The three-dimensional range of mandibular movements, including both functional and border movements, is known as the envelope of mandibular motion. This concept was first described by Ulf Posselt [2].

In Class II patients, increased overjet may compress the anterior portion of the sagittal envelope, whereas deep overbite may increase the vertical component of mandibular movement. Understanding these variations is essential when designing prosthetic occlusion.

Occlusal Morphology Considerations

When designing occlusal surfaces for prosthetic restorations in Class II patients, functional harmony should take precedence over exact replication of natural tooth anatomy. Reduced cusp height, shallow fossae, and wider occlusal tables may help accommodate altered mandibular movement patterns [19,20].

For removable prostheses, lingualized occlusion or flat occlusal schemes may provide improved stability and easier adjustment.

Clinical Implications

Successful prosthodontic management of Class II patients requires careful evaluation of mandibular movement patterns, functional dynamics, and occlusal relationships. Modern technologies such as digital articulators and computerized occlusal analysis have improved clinicians' ability to design precise occlusal schemes.

A simplified workflow for prosthodontic treatment planning in Class II patients is illustrated in Figure 2.

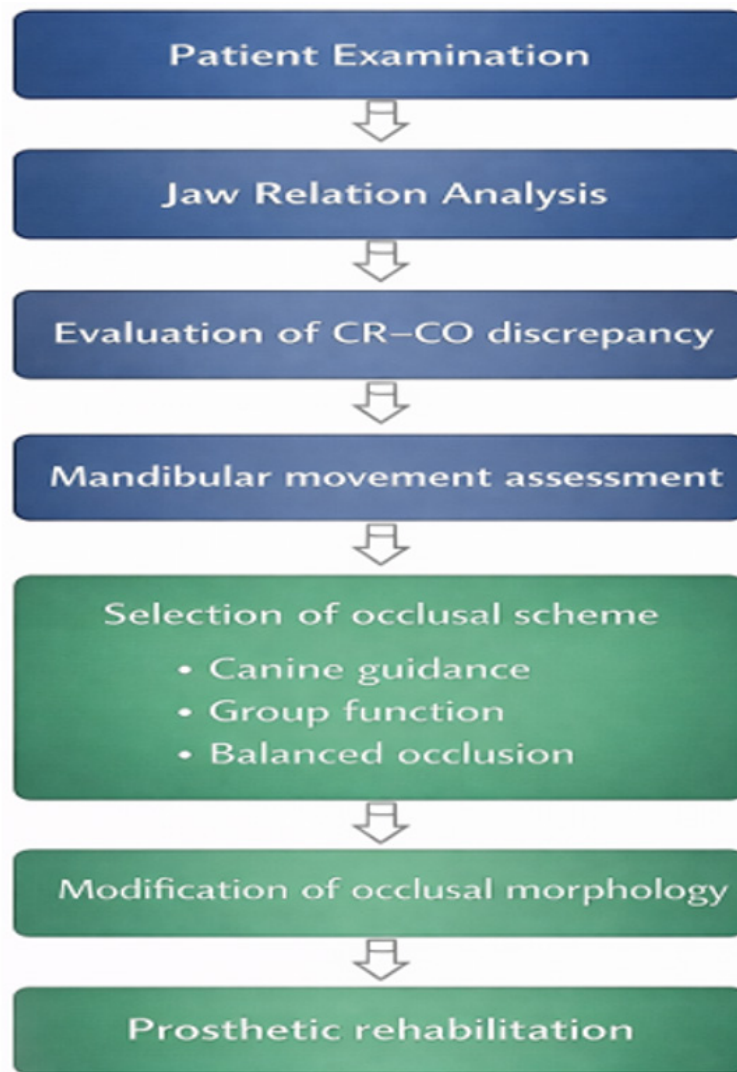


Figure 2. Prosthodontic Treatment Planning Workflow for Class II Patients.

CONCLUSION

Prosthodontic rehabilitation in patients with Class II jaw relations requires an individualized, function-driven approach rather than rely on conventional Class I occlusal concepts. Altered mandibular position, increased overjet, and modified condylar dynamics significantly influence occlusal relationships and mandibular movement patterns.

Clinically, occlusal morphology should be adapted by reducing cusp height, flattening fossae, and widening occlusal tables to minimize interferences and lateral forces. Careful control of anterior guidance is essential to achieve effective posterior disocclusion and protect restorations. Accurate recording and management of centric relation-centric occlusion discrepancies remain critical for ensuring occlusal stability. Selection of occlusal schemes should be tailored to functional requirements and prosthesis type.

This review highlights the need to integrate anatomical and biomechanical considerations into occlusal design and

underscores the role of digital tools in improving precision. Future research should focus on long-term clinical outcomes of occlusal schemes in Class II patients and the validation of digital workflows to establish evidence-based, standardized guidelines.

REFERENCES

1. Clayton JA. (1995). Occlusion and prosthodontics. *Dent Clin North Am.* 39(2):313-333.
2. Sailer I. (2024). The Importance of Occlusion and Function in Modern Prosthodontics: A Focus on New Restorative Materials. *Int J Prosthodont.* 37(5):493-494.
3. Kaje R, Rashme R, Manimegalan P, Vundela RR, Saidalavi SK, Jadhav AV. (2024). Assessing the Efficacy of Early versus Late Orthodontic Intervention in the Management of Class II Malocclusion: A Comparative Analysis. *J Pharm Bioallied Sci.* 16(Suppl 3):S2691-S2693.

4. Ma Y, Zhao W, Zhang S, Jin X, Xu J, Fu B, et al. (2024). Treatment decisions of patients with Class II Division 2 malocclusion and severe tooth wear: a systematic review. *BDJ Open*. 10(1):65.
5. Abduo J, Lyons K. (2019). Clinical considerations for increasing occlusal vertical dimension: a review. *Aust Dent J*. 64(1):2-13.
6. Alqutaibi AY, Aboalrejal AN, et al. (2022). Occlusal considerations in prosthodontics: current concepts. *J Prosthodont Res*. 66(3):345-356.
7. Zarb GA, Eckert SE, Jacob RF, et al. (2023). *Prosthodontic treatment for edentulous patients*. 14th ed. Elsevier.
8. Dawson PE, editor. (2021). *Functional occlusion: from TMJ to smile design*. Updated ed. Elsevier.
9. Kandasamy S, Greene CS. (2020). The evolution of occlusion and temporomandibular disorders. *Orthod Craniofac Res*. 23(S1):7-12.
10. Manfredini D, Lombardo L, Siciliani G. (2017). Temporomandibular disorders and dental occlusion: systematic review. *Prog Orthod*. 18:10.
11. Koyano K, Tsukiyama Y, Ichiki R, Kuwata T. (2018). Assessment of occlusion in prosthodontic treatment. *J Oral Rehabil*. 45(5):363-369.
12. Proffit WR, Fields HW, Sarver DM. (2023). *Contemporary orthodontics*. 7th ed. Elsevier.
13. Alhammadi MS, Halboub E, Fayed MS, Labib A, El-Saaidi C. (2018). Global distribution of malocclusion traits: A systematic review. *Dental Press J Orthod*. 23(6):40.e1-40.e10.
14. Ferrario VF, Sforza C. (2018). Biomechanics of occlusion and mastication. *Ann Anat*. 216:52-62.
15. Serra-Negra JM, Paiva SM, et al. (2021). Occlusal factors and their role in prosthodontics. *Clin Oral Investig*. 25:2335-2344.
16. Al-Dwairi ZN, Lynch CD. (2017). Fixed prosthodontics and occlusal considerations. *Dent Update*. 44(3):238-246.
17. Witter DJ, Kreulen CM, Mulder J, Creugers NH. (2019). Occlusal stability and functional dentition. *J Dent*. 87:103-110.
18. Türp JC, Schindler HJ. (2017). The dental occlusion as a suspected cause for TMDs: epidemiological perspective. *J Oral Rehabil*. 44(7):502-512.
19. De Kok IJ, Chang SS, et al. (2016). Managing occlusion in implant-supported prostheses. *Compend Contin Educ Dent*. 37(3):e1-e9.
20. Bidra AS, Agar JR, Parel SM. (2019). Implant prosthodontics and occlusion. *J Prosthet Dent*. 121(2):157-162.