

Amyand's Hernia, an Unusual Inguinal Hernia. A Case Report

Eduardo Esteban-Zubero^{1*}, Myriam Andrés-Matías², Moisés Alejandro Alatorre-Jiménez^{3,4}, Alejandro Marín-Medina⁵, Laura Morros-Blanco⁶, Ada Soto Brambila⁵, Sabrina Diaram- Strand⁴, Carlos Arturo López-García⁷, Daniela Delgado de Lara⁸, Cristina García-Muro⁹

¹Emergency Department, Hospital San Pedro, Logroño, Spain.

²Department of Surgery, Hospital San Pedro, Logroño, Spain.

³Department of Pediatrics, SUNY Downstate, Brooklyn, NY, USA 11203

⁴Research Department, Asociación Mexicana de Atrofia Muscular Espinal (AMAME). Chápala 26, 44101. Guadalajara, Mexico.

⁵Department of Genetics, Western biomedical research center, Mexican Institute of Social Security. Guadalajara, Mexico.

⁶Elizalde Health Center, Logroño, Spain

⁷Department of Pathology and Genomic Medicine, Methodist Hospital, Weill Medical College of Cornell University, Houston, USA

⁸Department of Neuroscience, Western biomedical research center, Mexican Institute of Social Security, Guadalajara, Mexico

⁹Department of Pediatrics, Hospital San Pedro, Logroño, Spain.

Corresponding Author: Eduardo Esteban Zubero, Emergency Department of Hospital San Pedro. Calle Piqueras 98. ZIP Code: 26006. Logroño, Spain, **Tel:** +34654123994; **Email:** eezubero@gmail.com

Received Date: 17 Sep 2018

Accepted Date: 10 Oct 2018

Published Date: 11 Oct 2018

Copyright © 2018 Esteban-Zubero E

Citation: Esteban-Zubero E, Andrés-Matías M, Alatorre-Jiménez MA, Marín-Medina A, et al. (2018). Amyand's Hernia, an Unusual Inguinal Hernia. A Case Report. M J Case. 3(2): 041.

ABSTRACT

A 60 years old man was admitted in the Emergency Room referring right inguinal pain. The symptomatology was initiated 4 hours before and the patient did not refer any further symptoms. Physical examination revealed a tender and not erythematous mass difficult to reduce in the right inguinal area. An ultrasonography was also realized observing a hernial sac in the inguinal area, which presents approximate diameters of 32x12x11 millimeters. Abdominal fat content as well as the vermiform appendix without inflammatory changes were observed inside the hernial sac. The presence of the vermiform appendix inside the hernial sac is known as Amyand's hernia. Inguinal hernia was reduced totally and the patient was discharged from the Emergency Room realizing an elective hernioplasty with mesh in a second time.

Amyand's hernia is a rare entity defined by the presence of the vermiform appendix into an inguinal hernia. This pathology has an incidence of 1% and is complicated by acute appendicitis in 0.1 % of cases. It is more frequently observed in neonates and in older male patients. Diagnosis may be produced during the surgery if the vermiform appendix is not altered, or previously if the appendix is inflamed, perforated, or gangrenous due to the clinical symptoms as well as diagnosis tests performed (ultrasound or computed tomography). Classical treatment includes appendectomy, drainage of abscesses if existent, reduction of hernia, and hernioplasty. If exists inflammation, peritonitis or cecum incarceration, right hemicolectomy might be necessary. However, if appendix is not inflamed, prophylactic appendectomy is discussed.

KEY WORDS

Amyand's Hernia; Inguinal Hernia; Abdominal Pain; Strangulated Hernia.

INTRODUCTION

An inguinal hernia may content the urinary bladder, an ovary, the fallopian tube, diverticulitis of the colon, or the vermiform appendix. The last one was described in first time by Claudius Amyand in 1736 [1]. Although an inguinal hernia is common, Amyand's hernia has an incidence of 1% and is complicated by acute appendicitis in 0.1 % of cases [2]. If the vermiform appendix is not altered, most of these cases are diagnosed during the surgery.

The aim of this study is to summarize briefly this entity a purpose of a case of a 60 years old man affected by Amyand's hernia.

CASE REPORT

A 60 years old man without any interesting medical history was admitted in te Emergency Room referring right inguinal pain. The symptomatology was initiated 4 hours before and the patient did not refer any further symptoms. Physical examination revealed a tender and not erythematous mass difficult to reduce in the right inguinal area. Suspecting a complicated inguinal hernia, blood test analysis as well as abdominal radiography were performed. These diagnosis test did not reveal any disturbs. An ultrasonography was also realized observing a hernial sac in the inguinal area, which presents approximate diameters of 32x12x11 milimeters. Abdominal fat content as well as the vermiform appendix without inflammatory changes were observed inside the hernial sac. The appendix did not clearly exceed 6 mm of diameter and it was showed to be totally compressible (Figure 1).

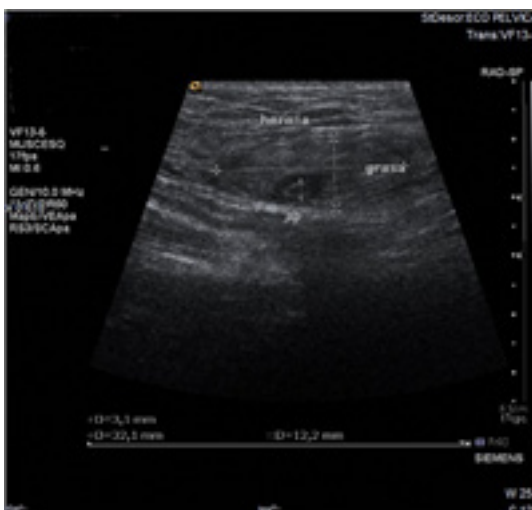


Figure 1: Ultrasound showing a hernial sac in the inguinal area with diameters of 32x12x11 milimeters. Abdominal fat content as well as the vermiform appendix without inflammatory changes were observed inside the hernial sac.

With the diagnosis of Type 1 Amyand's hernia, inguinal hernia was reduced totally after the administration of a diazepam injection (5 mg, endovenously). The patient was discharged

from the Emergency Room realizing an elective hernioplasty with mesh in a second time.

DISCUSSION

Amyand's hernia has an incidence of 1% and is complicated by acute appendicitis in 0.1 % of cases [2]. This entity is more common in male patients and presents a bimodal age distribution being more frequently observed in neonates and in older patients (>70 years) [3, 4]. Some studies observed that Amyand's hernia is about 3 times more common in the pediatric population [2].

Clinical signs and symptoms strongly depends on the situation of the vermiform appendix. Physical examination will usually reveal swelling in the right groin, pain, and tenderness. Due to that, it is difficult to distinguish it from an incarcerated or strangulated inguinal hernia [2]. Unlike typical pain of hernia, pain tends to be crampy and episodic and not dull, and its duration may be 24 hours in adults and up to 72 hours in children [4, 5]. Attending to the vermiform appendix affectation (normal, inflamed, perforated, or gangrenous), symptomatology may include fever, vomiting, gastrointestinal symptoms, and bowel obstruction. However this connection is inconsistent due to the neck of the hernia will usually prevent the spread of inflammation and limit peritoneal irrigation [4]. Whereas inflammation markers (white blood cell count, C-reactive protein) are inconsistently connected with the status of the vermiform appendix, peritoneal irrigation as well as older age are considered worse prognostic factors [5].

Diagnosis is usually realized during hernia surgery. Preoperative diagnosis is difficult and it is made with ultrasound (US) or computed tomography (CT) [6]. The differential diagnosis of this disease may include strangulated hernia, strangulated omentocoele, Richter's hernia, inguinal adenitis, orchiepididymitis, incompletely descended testis, acute epididymitis, testicular tumor with hemorrhage, and acute hidrocele [2]. In US, the appearance of a thick-walled tubular structure connecting with the cecum and ending with the blind end in the hernia sac is used for diagnosis. If this strucutre is greater than 6 milimeters, acute apendicitis is diagnosed [6]. Both techniques help to distinguish between the four basic types of Amyand's hernia described by Losanoff and Basson, which should be treated differently [7]. Table 1 summarizes this classification.

Classical treatment includes appendectomy, drainage of abscesses if existent, reduction of hernia, and hernioplasty. If exists inflammation, peritonitis or cecum incarceration, right hemicolectomy might be necessary [2]. However, if appendix is not inflamed, prophylactic appendectomy is discussed [4]. Whereas some authors support appendectomy in young patients because appendix is prone to reherniate [8], others believe that appendectomy ads to operative risk [4]. Attending

to the hernia repair, some authors suggest that mesh should not be used in cases of appendicitis of perforated appendix. This theory is supported in an increased risk of wound infection, sepsis, and fistula formation. On the other hand, in non-inflamed cases, the use of mesh is well accepted [2]. A mesh repair is mandatory in recurrent inguinal hernias [5]. Losanoff and Basson in its Amyand’s hernia classification described the treatment according to the vermiform appendix status. This statement is used nowadays to establish the treatment (Table 1).

Table 1: Clasification of Amyand’s hernia described by Losanoff and Basson.

CLASSIFICATION	DESCRIPTION	SURGICAL MANAGEMENT
Type 1	Normal appendix with an inguinal hernia	Hernia reduction, mesh repair, appendectomy in young patients
Type 2	Acute appendicitis within an inguinal hernia, no abdominal sepsis	Appendectomy through hernia, primary endogenous repair of hernia, no mesh
Type 3	Acute appendicitis within an inguinal hernia, abdominal wall, or peritoneal sepsis	Laparotomy, appendectomy, primary repair of hernia, no mesh
Type 4	Acute appendicitis within an inguinal hernia, related or unrelated abdominal pathology	Manage as types 1 to 3 hernia, investigate or treat second pathology as appropriate

In conclusion, Amyand’s hernia is a rare pathology diagnosed frequently incidentally intraoperative. If this disease is suspected, US or CT are necessary to confirm the diagnosis. Attending to the subtype of Amyand’s hernia, diagnosis and treatment differs. Like our case, if vermiform appendix is not affected, treatment includes hernia reduction and repair of the hernia in a second time. The decision to perform prophylactic appendectomy must take into account individual factors that may increase morbidity.

REFERENCES

1. Vehbi H, Agirgun C, Agirgun F and Dogan Y. (2016). Preoperative diagnosis of Amyand’s hernia by ultrasound and computed tomography. *Turk J Emerg Med.* 16(2):72-74.

2. Michalinos A, Moris D and Vernadakis S. (2014). Amyand’s hernia: a review. *Am J Surg.* 207(6): 989-995.

3. Meinke AK. (2007). Review article: appendicitis in groin hernias. *J Gastrointest Surg.* 11(10): 1368-1372.

4. Cankorkmaz L, Ozer H, Guney C, Atalar MH, et al. (2010). Amyand’s hernia in the children: a single center experience. *Surgery.* 147(1): 140-143.

5. Inan I, Myers PO, Hagen ME, Gonzalez M, et al. (2009). Amyand’s hernia: 10 years’ experience. *Surgeon.* 7(4): 198-202.

6. Guler I, Alkan E, Nayman A and Tolu I. (2016). Amyand’s Hernia: Ultrasonography Findings. *J Emerg Med.* 50(1): e15-e17.

7. Losanoff JE and Basson MD. (2008). Amyand hernia: a classification to improve management. *Hernia.* 12(3): 325-326.

8. Priego P, Lobo E, Moreno I, Sánchez-Picot S, et al. (2005). Acute appendicitis in an incarcerated crural hernia: analysis of our experience. *Rev Esp Enferm Dig.* 97(10): 707-715.